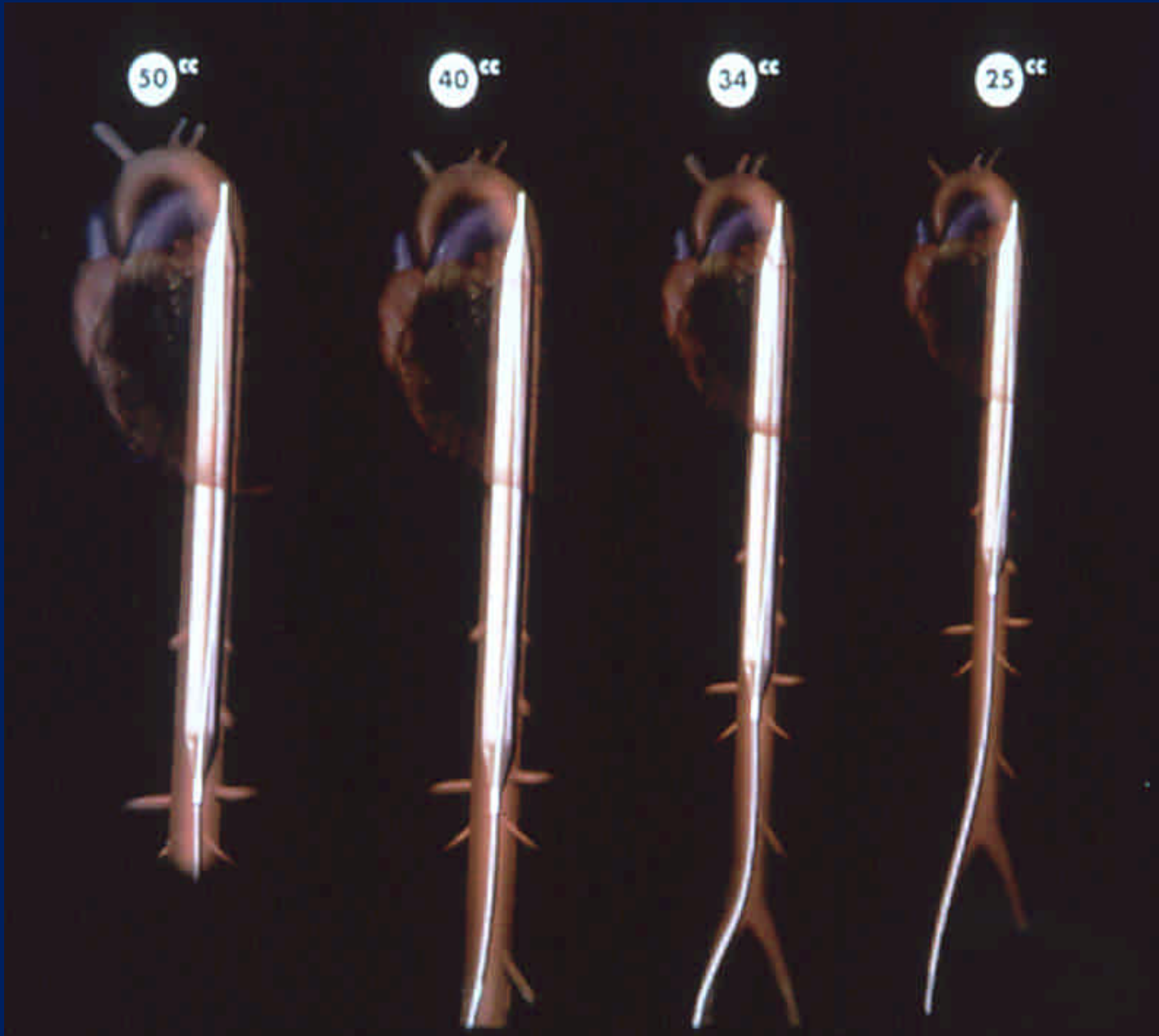


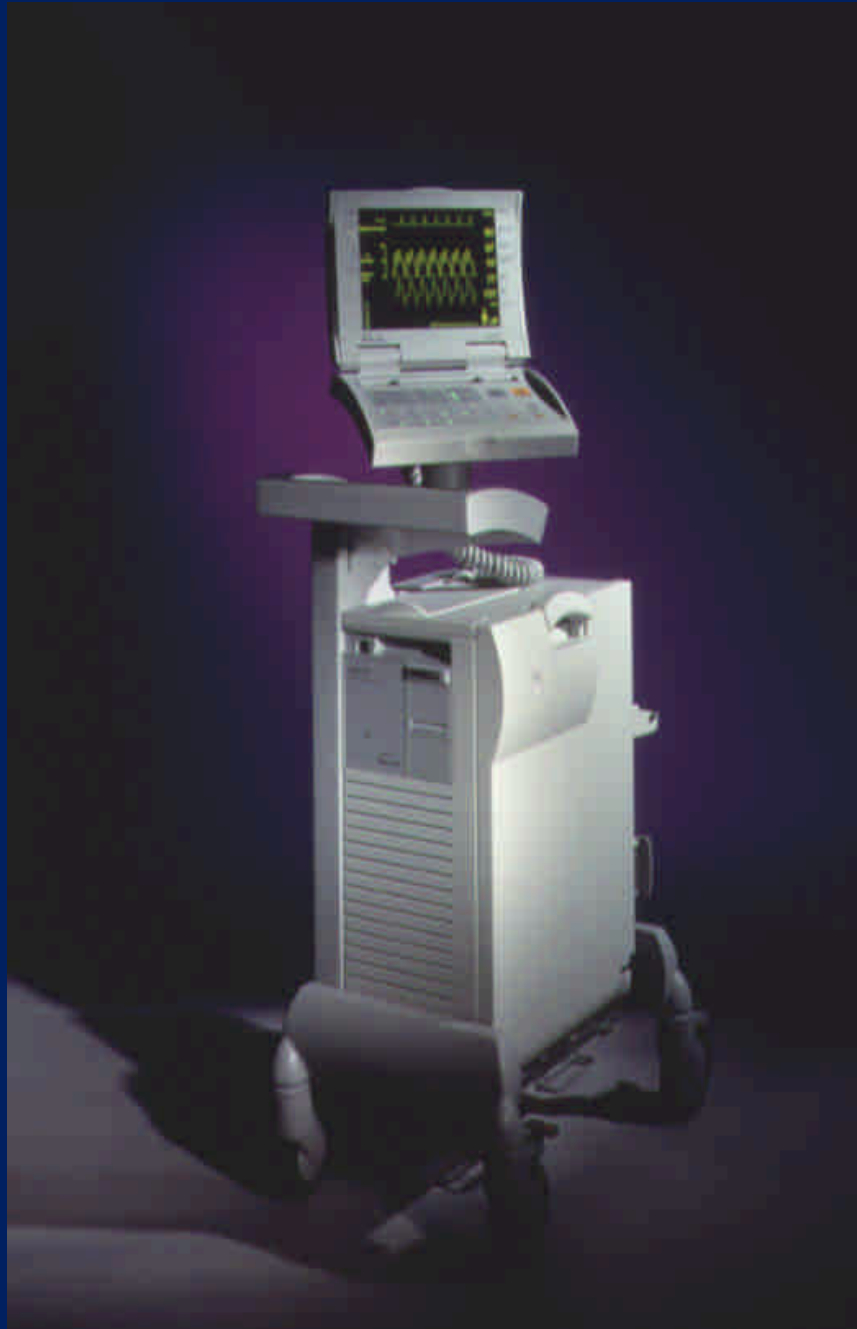Ballon de contre-pulsion intra-aortique

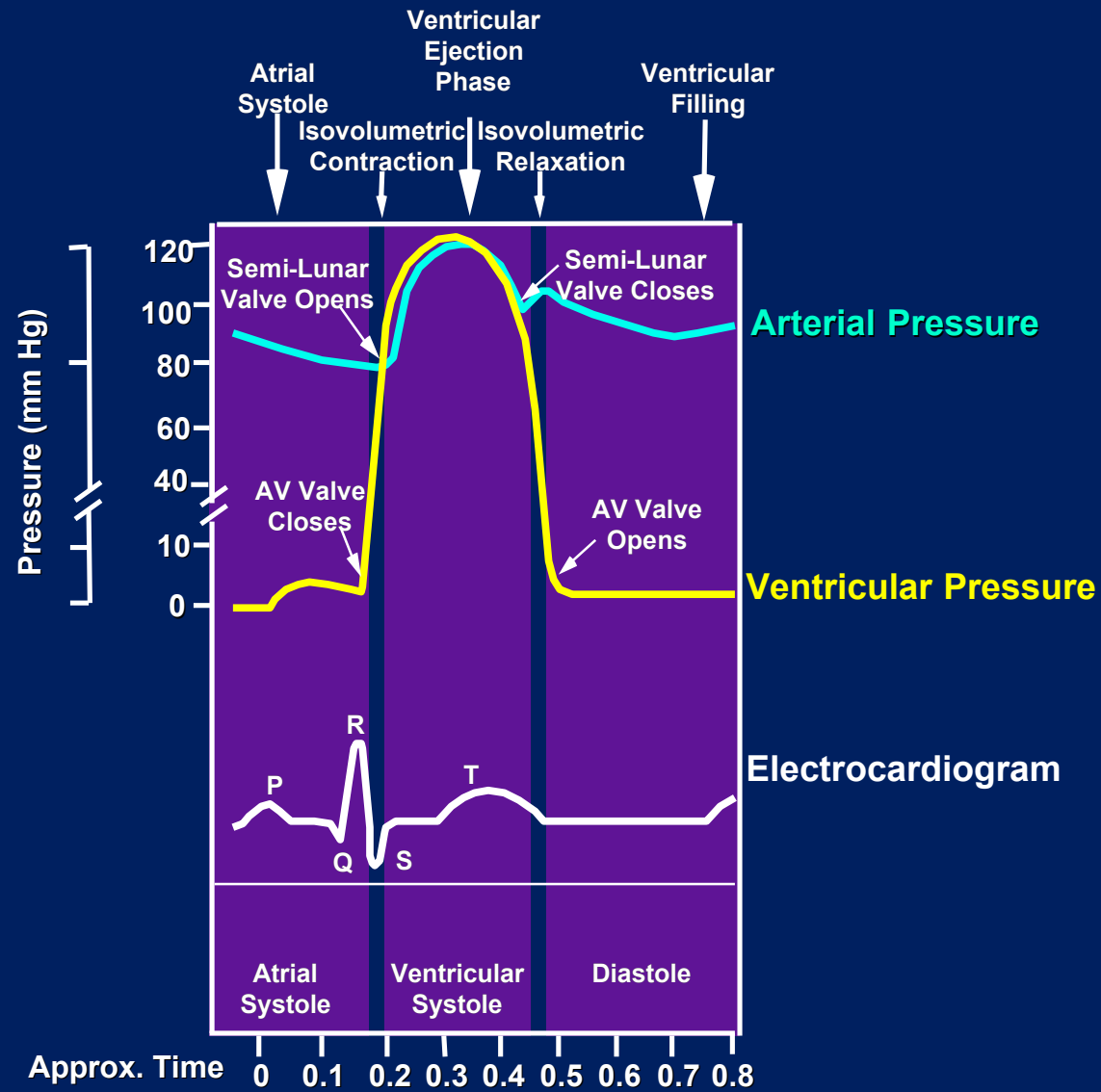
Mme Margrit Cohen

Dr P. F Keller

2.10.07

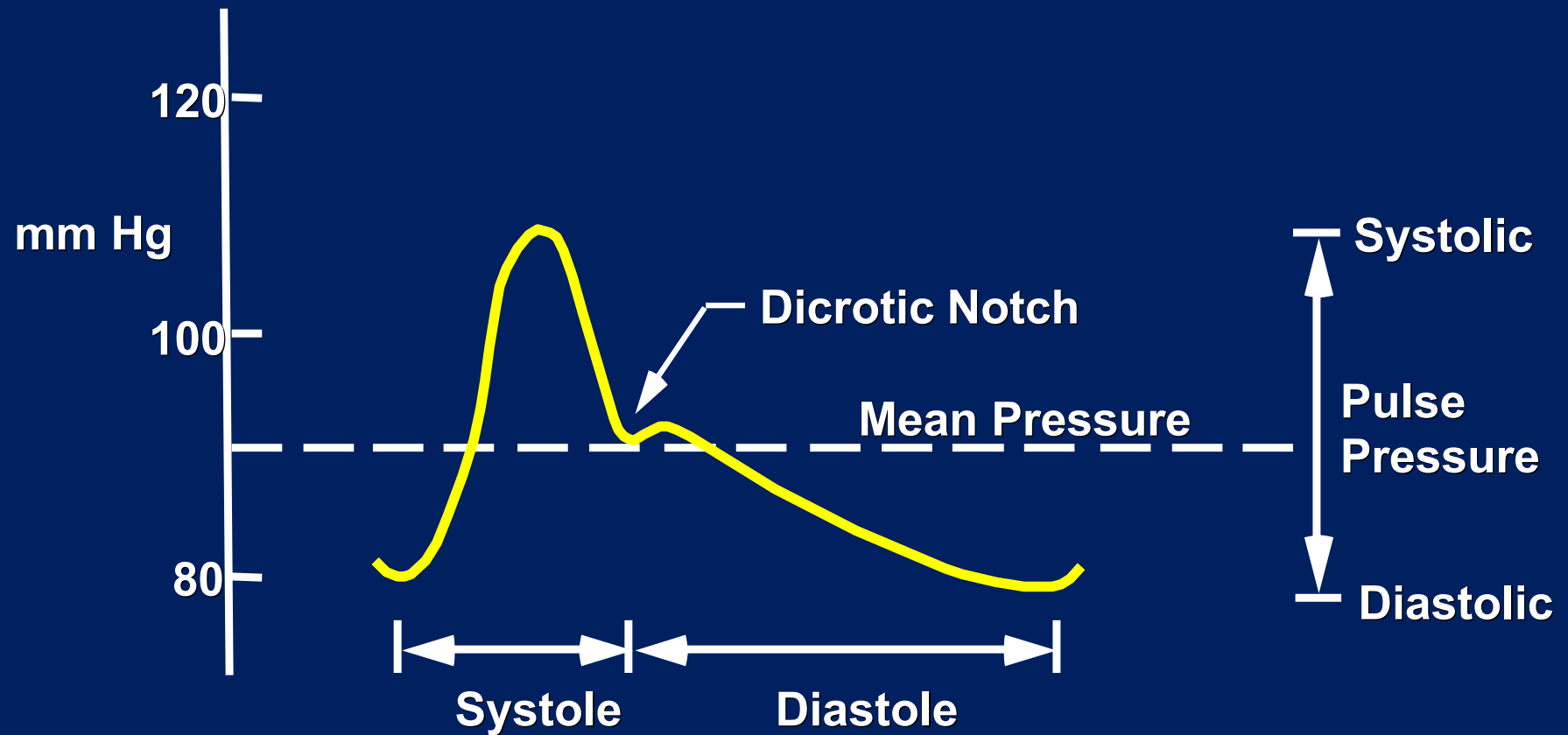


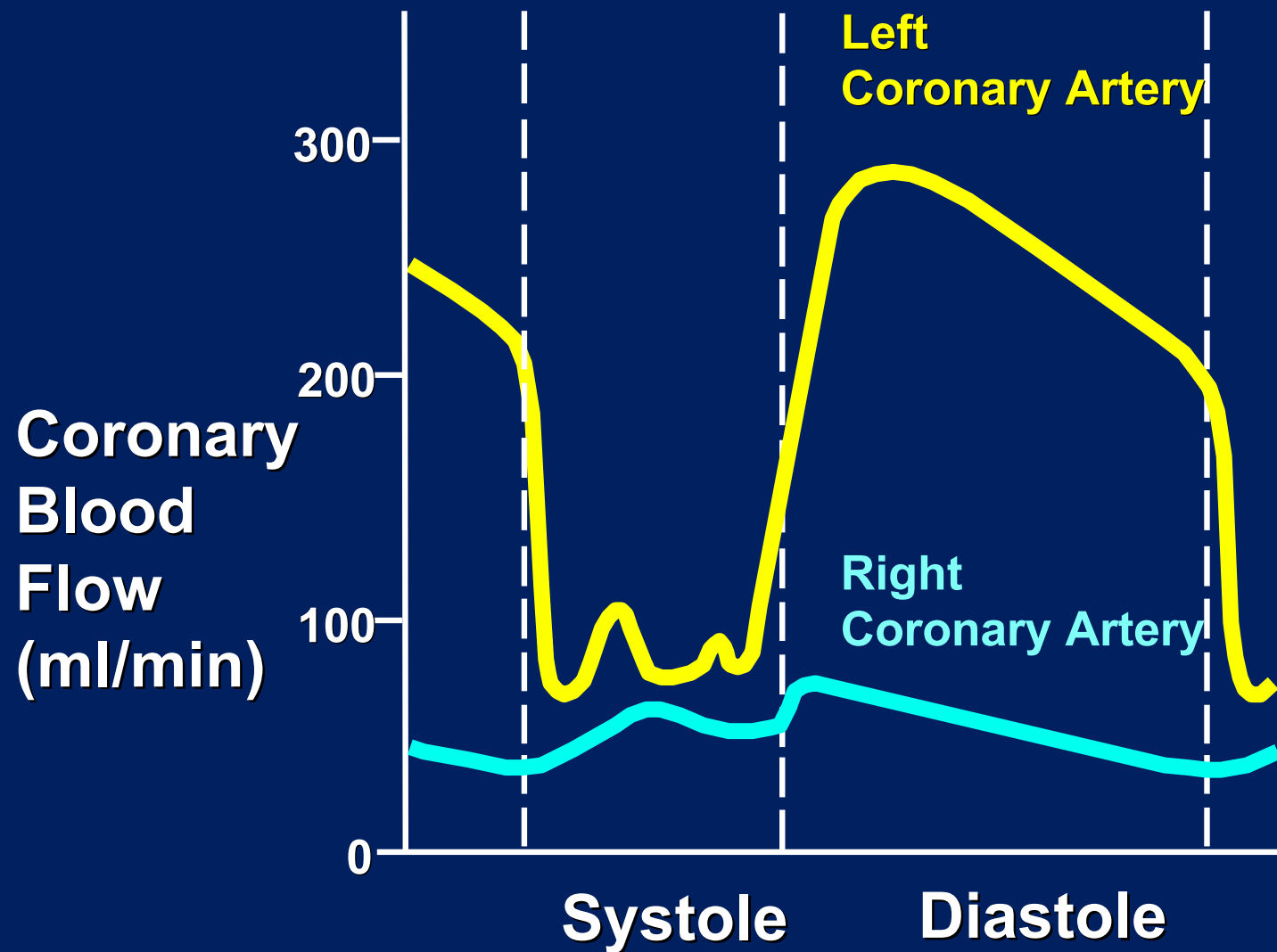




Arterial Pressure Curve

Aortic Pressure Waveform



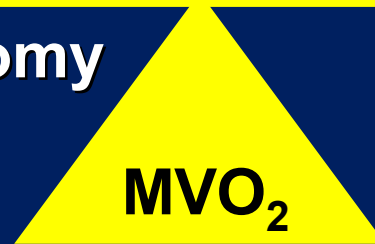

Slide courtesy of A.C. Guyton, MD from Textbook of Medical Physiology, Sixth Edition, 1981, W.B. Saunders Company

DETERMINANTS OF MYOCARDIAL OXYGEN SUPPLY AND DEMAND

Supply


Coronary artery anatomy
Diastolic pressure
Diastolic time
O₂ Extraction
HBG
PaO₂



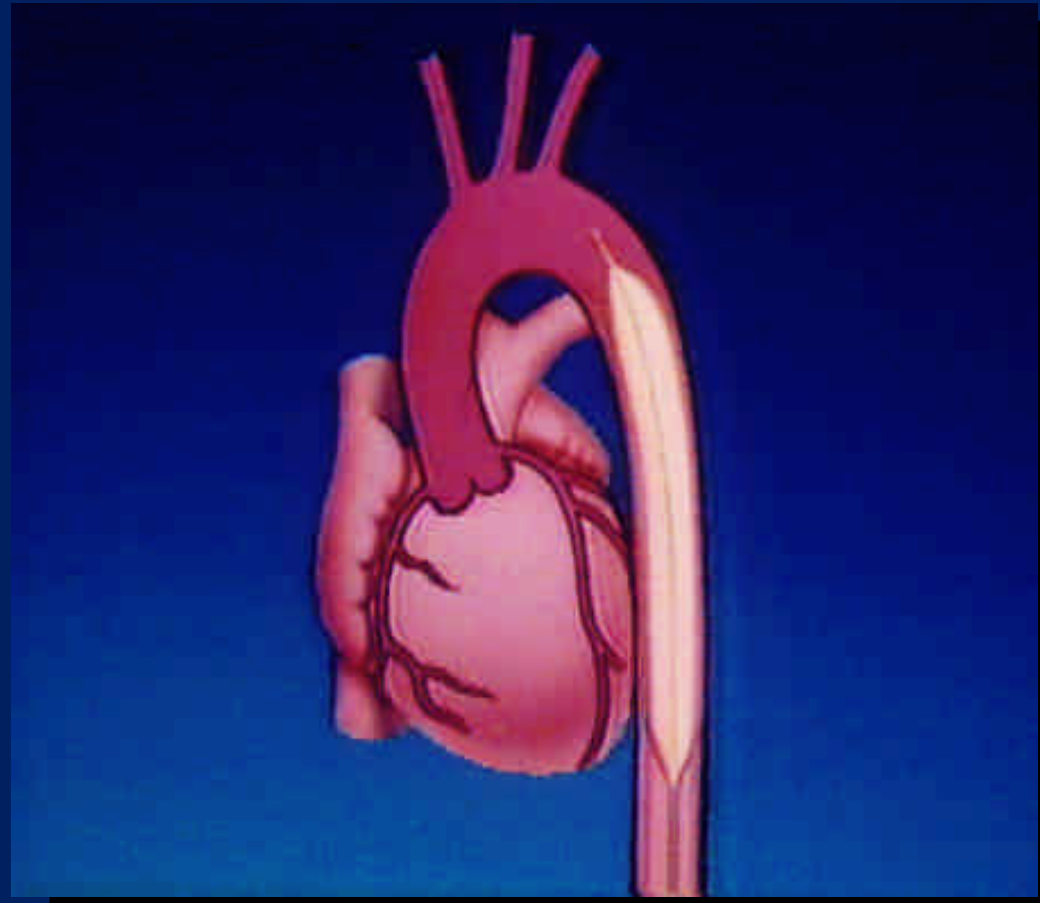
Demands

Heart rate
Afterload
Preload
Contractility

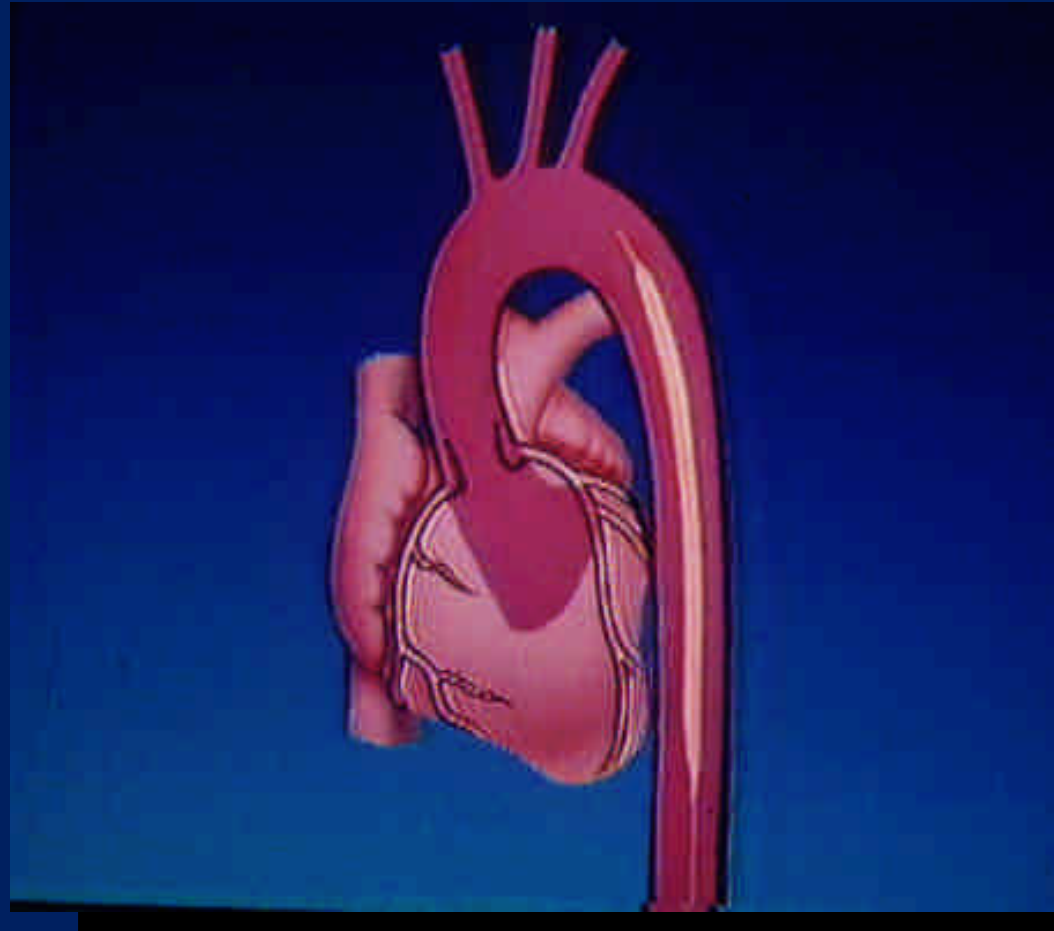
Left Ventricular Failure



IAB Inflation



IAB Deflation





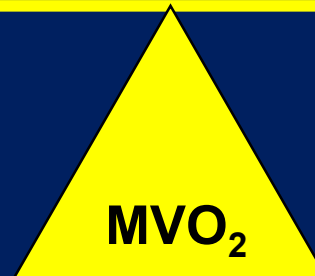Arterial Pressure

**Balloon Pump
Console**

Primary Effect of IAB Therapy

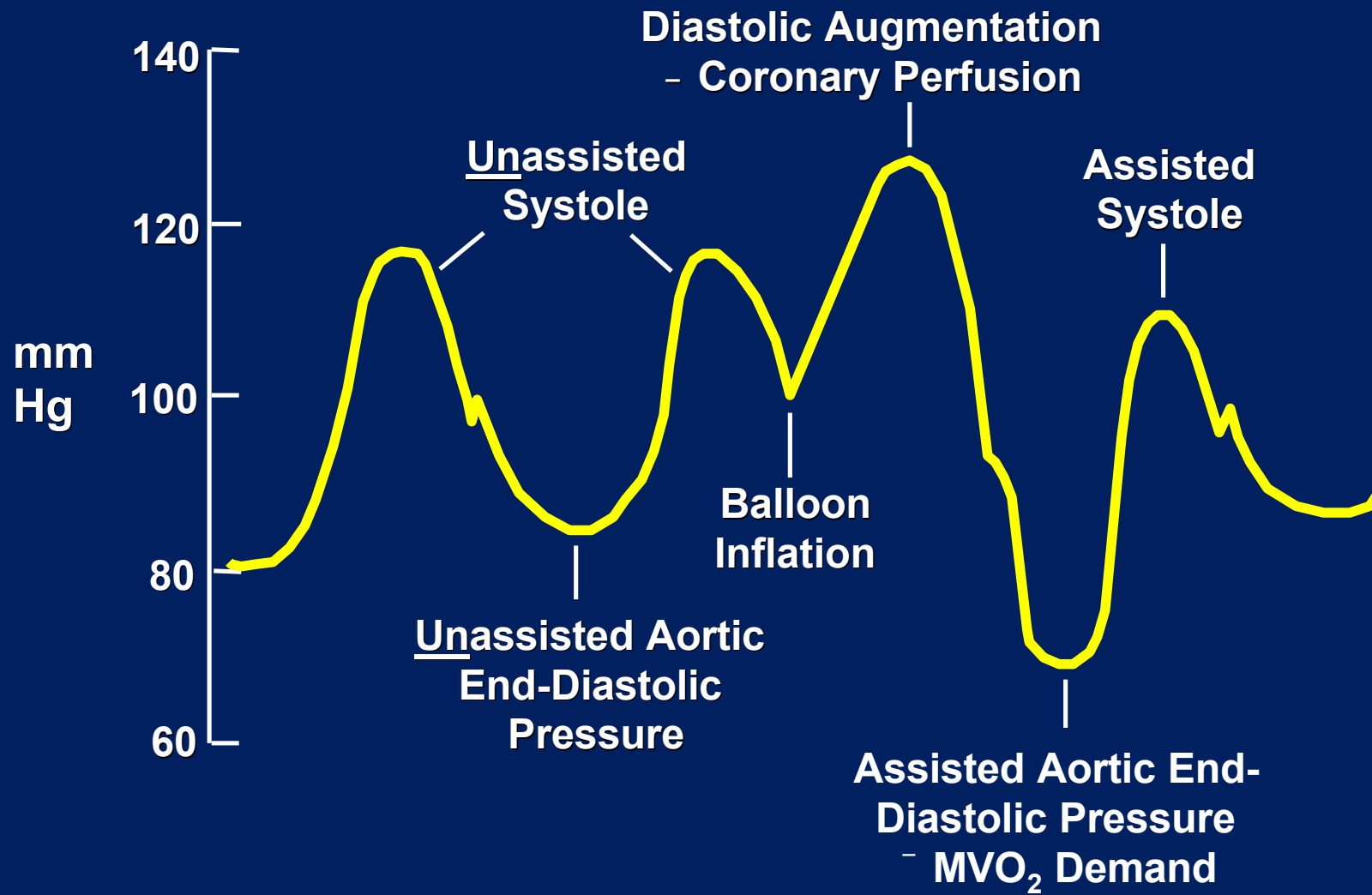
Supply

Demand



- Supply - IAB inflation
- Demand - IAB deflation

Arterial Waveform Variations During IABP Therapy



Physiologic Effects of IABP

Aortic Pressure	Cardiac	Blood Flow	LV Pressure	Left Ventricle
- Systolic	- Afterload	- Coronary blood flow	- Systolic	- Volume
- Diastolic	- Preload	- Cardiac output	- End - diastolic	- Stroke work
		- Renal blood flow		- Wall tension

Indications

1. Refractory ventricular failure
2. Cardiogenic shock
3. Unstable refractory angina

Indications

4. Impending infarction
5. Mechanical complications due to acute myocardial infarction
6. Ischemia related intractable ventricular arrhythmias

Indications

7. Cardiac support for high-risk general surgical and coronary angiography/angioplasty patients
8. Septic shock
9. Weaning from cardiopulmonary bypass

Indications

10. Intraoperative pulsatile flow generation
11. Support for failed angioplasty and valvuloplasty

Contraindications

1. Severe aortic insufficiency
2. Abdominal or aortic aneurysm
3. Severe calcific aorta-iliac disease or peripheral vascular disease
4. Sheathless insertion with severe obesity, scarring of the groin

Potential Side Effects and Complications

- Limb ischemia
- Bleeding at the insertion site
- Thrombocytopenia
- Immobility of the balloon catheter
- Balloon leak
- Infection
- Aortic dissection
- Compartment syndrome

Factors Affecting Diastolic Augmentation

1. Patient Hemodynamics

- Heart Rate
- Stroke Volume
- Mean Arterial Pressure
- Systemic Vascular Resistance

Factors Affecting Diastolic Augmentation

2. Intra-aortic Balloon Catheter

- IAB in sheath
- IAB not unfolded
- IAB position
- Kink in IAB catheter
- IAB leak
- Low Helium concentration

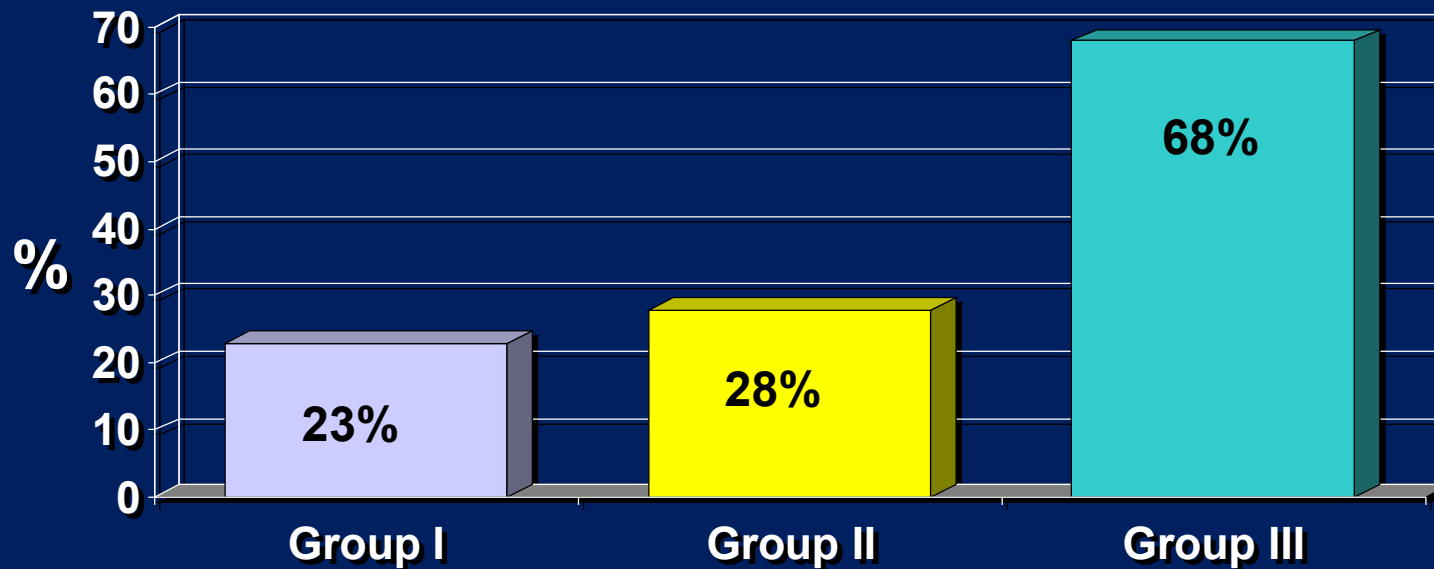
Factors Affecting Diastolic Augmentation

3. IABP

- Timing
- Position of the IAB augmentation control

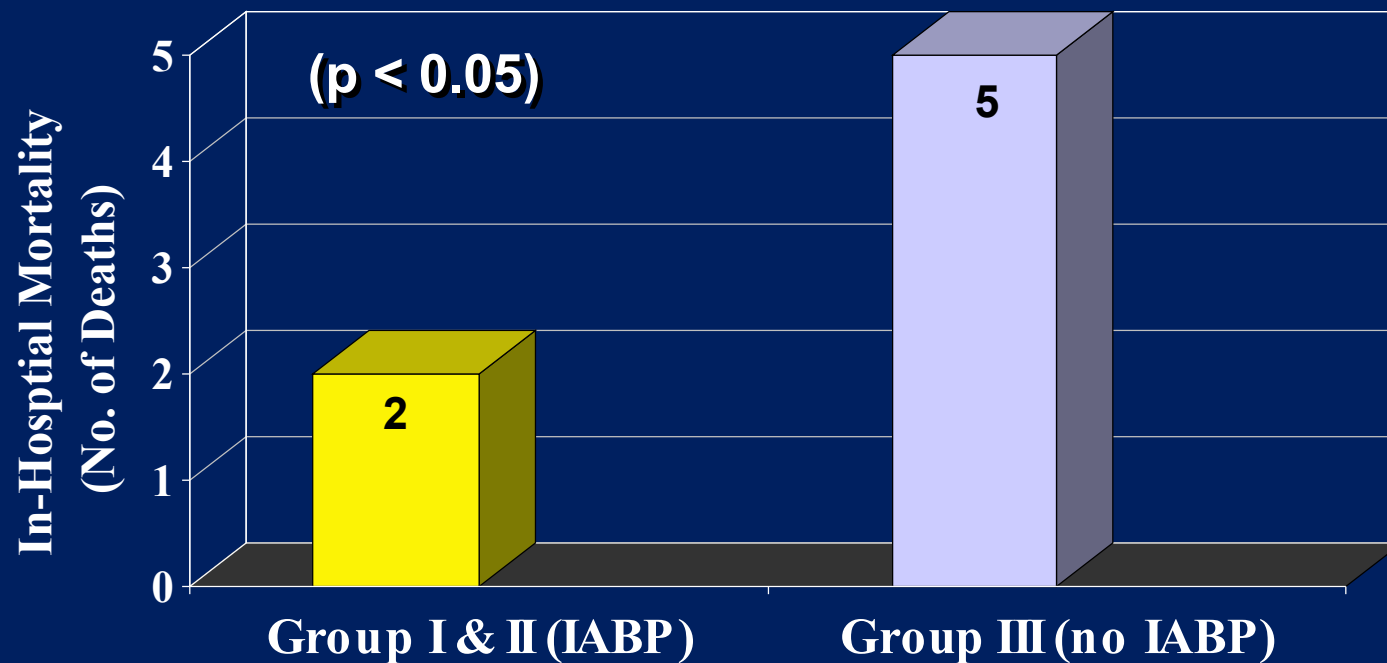
Acute MI and Cardiogenic Shock

Survival Rates for AMI and Cardiogenic Shock



Stomel, R, et al; *Chest* 1994; 105(4):997-1002

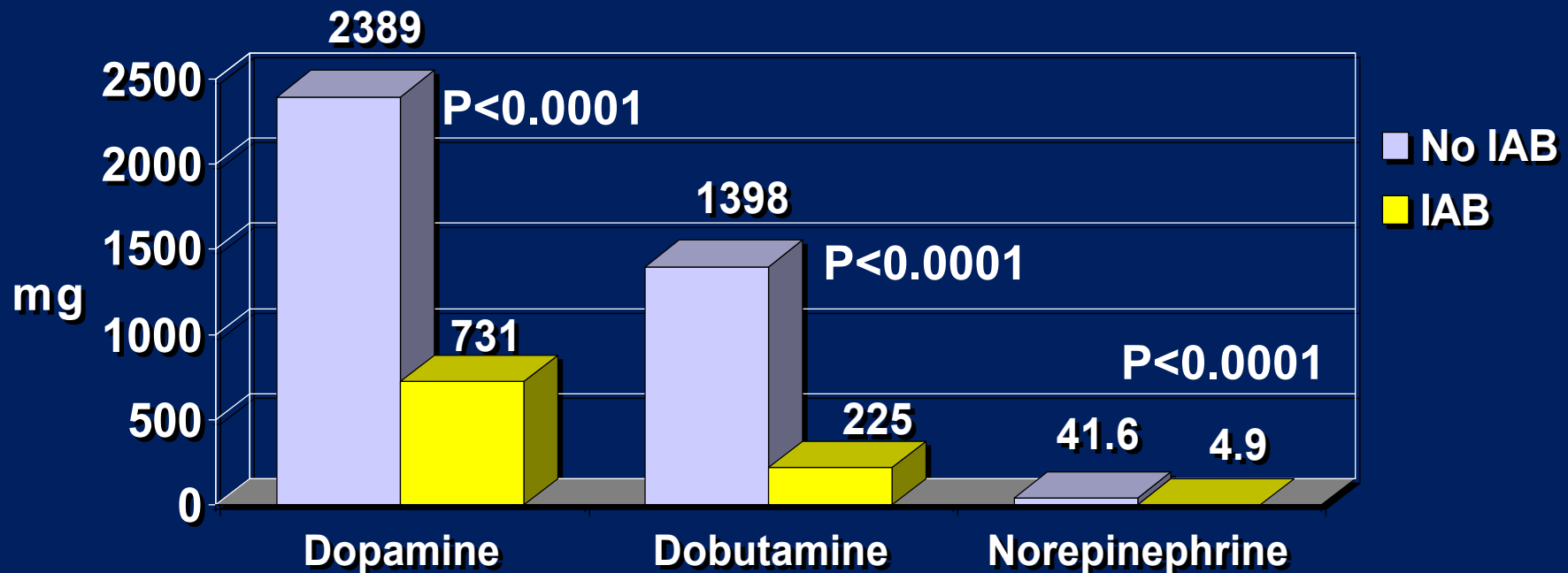
Evaluation of Preoperative IABP Support in High-Risk Coronary Patients



Christenson, JT, et al; *Eur J Cardiothorac Surg* 1997; 11:1097-1103

Preoperative IABP - Impact on Postoperative Inotropic Drug Use

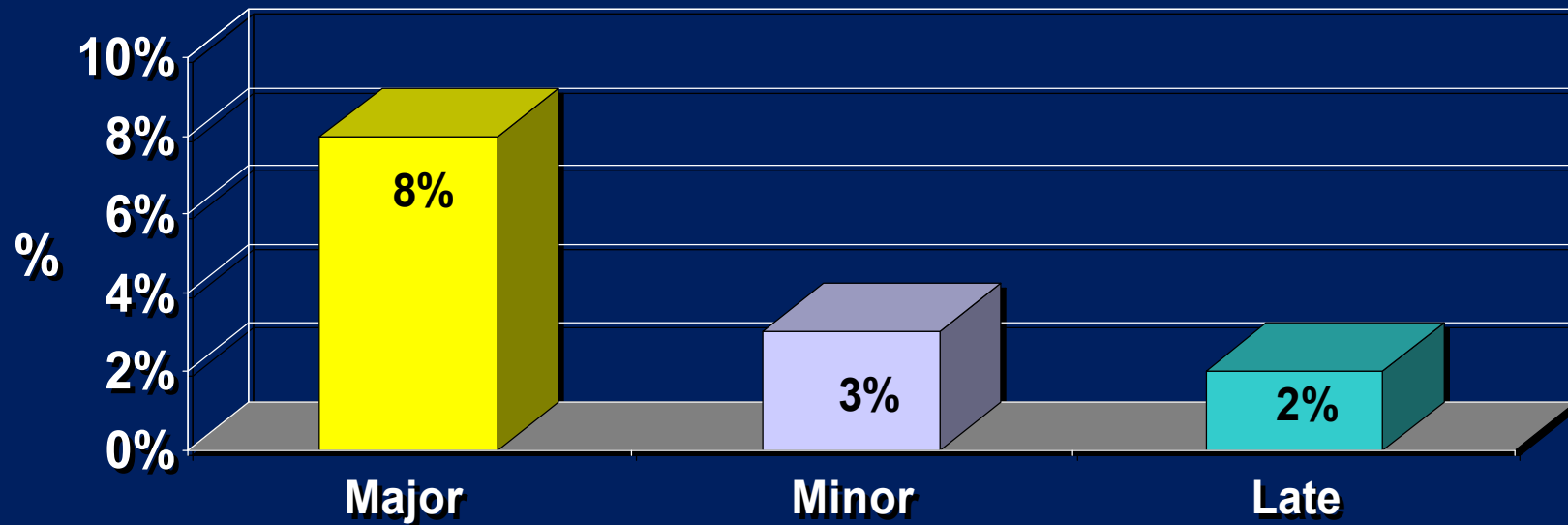
Postoperative Drug Consumption



Christenson, JT, et al; *Today's Therapeutic Trends* 1999;17(3):217-225

Vascular Complications

Vascular Complications



Arafa, OE, et al; *Ann Thorac Surg* 1999; 67:645-651

Timing Errors - Early Inflation

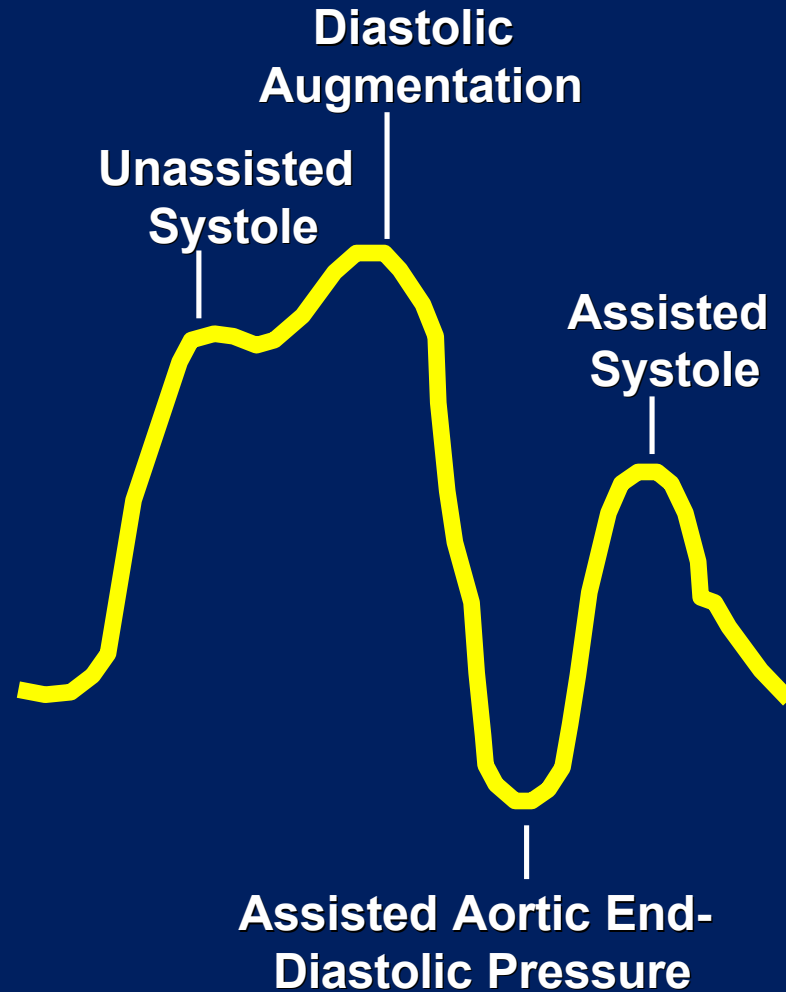
Inflation of the IAB prior to aortic valve closure

Waveform Characteristics:

- Inflation of IAB prior to aortic valve closure
- Diastolic augmentation encroaches onto systole (may be unable to distinguish)

Physiologic Effects:

- Potential premature closure of aortic valve
- Potential increase in LVEDV and LVEDP or PCWP
- Increased left ventricular wall stress or afterload
- Aortic regurgitation
- Increased MVO_2 demand



Timing Errors - Late Inflation

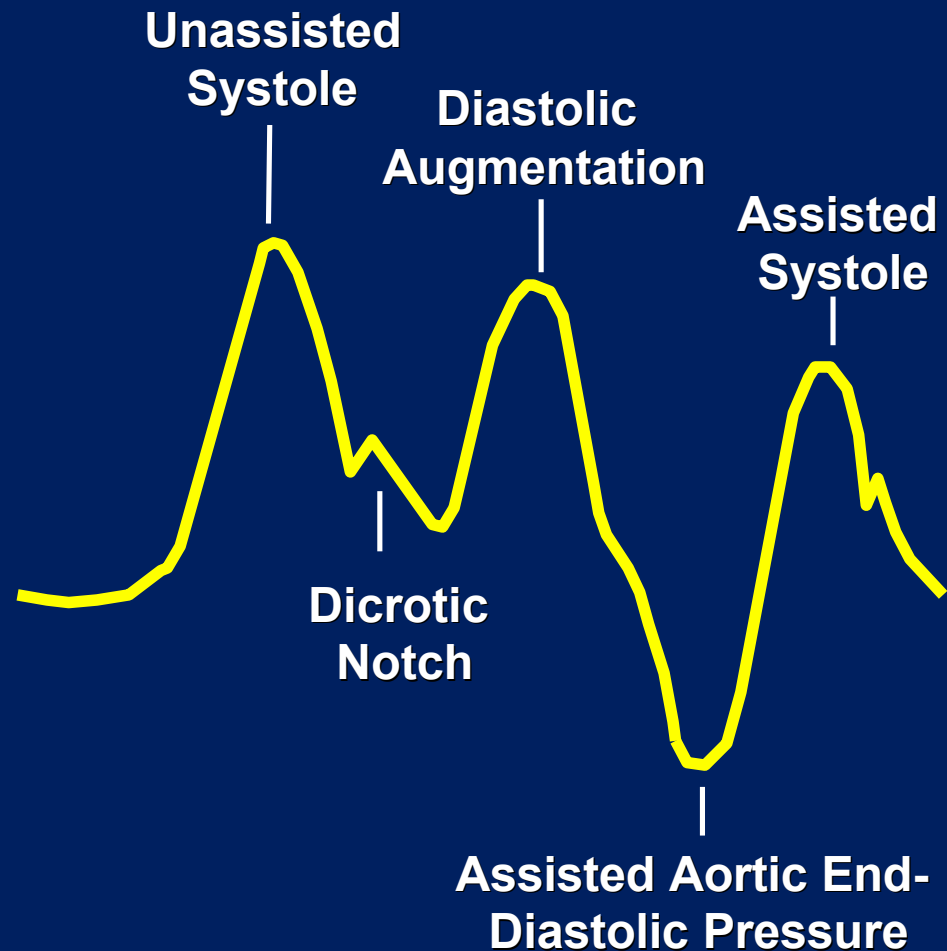
Inflation of the IAB markedly after closure of the aortic valve

Waveform Characteristics:

- Inflation of the IAB after the dicrotic notch
- Absence of sharp V
- Sub-optimal diastolic augmentation

Physiologic Effects:

- Sub-optimal coronary artery perfusion



Timing Errors - Early Deflation

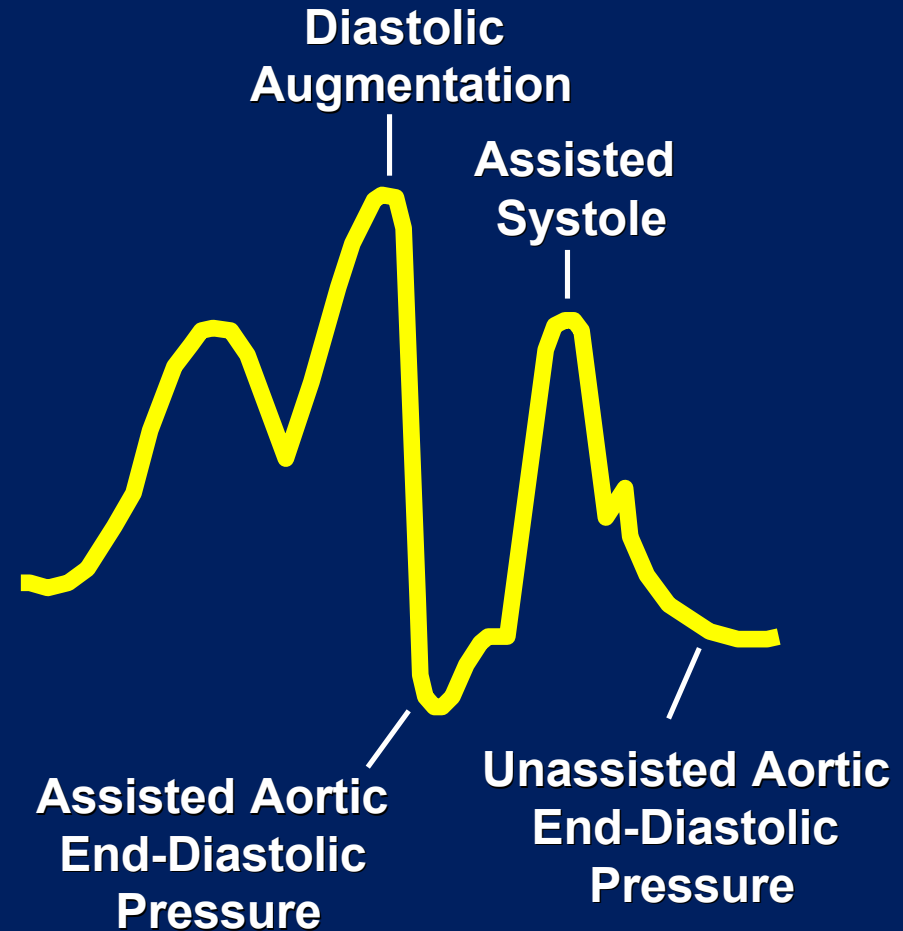
Premature deflation of the IAB during the diastolic phase

Waveform Characteristics:

- Deflation of IAB is seen as a sharp drop following diastolic augmentation
- Sub-optimal diastolic augmentation
- Assisted aortic end-diastolic pressure may be equal to or less than the unassisted aortic end-diastolic pressure
- Assisted systolic pressure may rise

Physiologic Effects:

- Sub-optimal coronary perfusion
- Potential for retrograde coronary and carotid blood flow
- Angina may occur as a result of retrograde coronary blood flow
- Sub-optimal afterload reduction
- Increased MVO_2 demand



Timing Errors - Late Deflation

Deflation of the IAB as the aortic valve is beginning to open

Waveform Characteristics:

- Assisted aortic end-diastolic pressure may be equal to the unassisted aortic end-diastolic pressure
- Rate of rise of assisted systole is prolonged
- Diastolic augmentation may appear widened

Physiologic Effects:

- Afterload reduction is essentially absent
- Increased MVO_2 consumption due to the left ventricle ejecting against a greater resistance and a prolonged isovolumetric contraction phase
- IAB may impede left ventricular ejection and increase the afterload

